

# Visual Outcome and Intraocular Lens Rotational Stability after Cataract Surgery with Multifocal Toric Intraocular Lens Implantation

Ewa Mrukwa-Kominek<sup>1,2</sup>, Agnieszka Malec-Pleskacz<sup>3</sup>, Monika Sarnat-Kucharczyk<sup>2</sup>

<sup>1</sup> Department of Ophthalmology, Faculty of Medical Sciences in Katowice, Medical University of Silesia, Katowice, Poland  
Head: Professor Dorota Wyględowska-Promieńska, MD, PhD

<sup>2</sup> Department of Ophthalmology, Professor K. Gibinski University Clinical Center, Medical University of Silesia, Katowice, Poland

Head: Professor Dorota Wyględowska-Promieńska, MD, PhD

<sup>3</sup> „Oko-Test” Dorożyński, Nowy Targ, Poland

## Abstract:

**Purpose:** To evaluate long-term refractive, visual outcomes and patient satisfaction following capsular bag implantation of a multifocal toric intraocular lens (IOL).

**Setting:** Department of Ophthalmology, Professor K. Gibinski University Clinical Center, Medical University of Silesia, Katowice, Poland.

**Methods:** This prospective, non-randomized study enrolled cataract patients with the presence of preoperative corneal astigmatism of values higher than 1.5 D. All patients were operated on by a single surgeon. After removal of cataract and injection of viscoelastic material, an intraocular lens was implanted into the capsular bag (M-flex T, Rayner Intraocular Lenses Limited, Hove UK). Postoperative examinations were performed at 1 day, 1 week, 1 month, 3 months, 6 months and the last visit (between 12 and 48 months).

**Results:** Thirty-five eyes were included in the analysis. The mean uncorrected distance visual acuity, corrected distance visual acuity, uncorrected near visual acuity, binocular distance visual acuity and binocular near visual acuity increased from  $0.28 \pm 0.23$ ,  $0.58 \pm 0.34$ ,  $0.29 \pm 0.21$ ,  $0.46 \pm 0.29$ ,  $0.45 \pm 0.25$  before the surgery to  $0.85 \pm 0.23$ ,  $0.88 \pm 0.16$ ,  $0.68 \pm 0.15$ ,  $0.94 \pm 0.13$ ,  $0.71 \pm 0.14$ , respectively, at the 3-month follow-up. All the values remained at the same level of statistical significance ( $P < 0.0001$ ). The mean preoperative cylinder power was  $-2.15$  D, which was reduced to  $-0.01$  D,  $0.43$  D at the 3-month visit. Higher contrast sensitivity was evident throughout all spatial frequencies of 3, 6, 12 and 18 after the surgery. The patients' satisfaction, measured by the VF-14 questionnaire, was significantly higher after the surgery, 82.67%, compared to with 41.62% before surgery. Moreover, a significant increase in spectacle independence after surgery was evident, with 90.20% spectacle free.

**Conclusions:** Implantation of a multifocal toric intraocular lens is a good option for patients to reduce their dependency on spectacles. The visual outcomes after surgery contribute to a high level of patient satisfaction and an improvement in quality of life.

## Key words:

multifocal toric intraocular lens, rotational stability, visual acuity, cataract surgery.

## Introduction

While cataract is the leading cause of blindness worldwide [1], most developed Western populations have access to cataract surgery [2]. It has been estimated that between 15 and 30% of patients with cataracts also have concomitant corneal or refractive astigmatism [3, 4]. Peer review publications on the topic indicate that around 30% of cataract patient have more than 0.75 diopters (D) of corneal astigmatism, with 22% having  $>1.5$  D and 8% having  $>2.00$  D [2, 3]. Another publication by Vitale et al. estimated that up to 50% of the US population aged over 60 years has 1.00 D or more of astigmatism [5]. It has been shown that a residual astigmatic error of 1.50–3.0 D after cataract surgery decreases uncorrected visual acuity (UCVA) to 20/70 or 20/100, respectively, and may also interfere with spectacle independence after multifocal intraocular lens (IOL) implantation [6]. To overcome this problem, astigmatism can be corrected during the cataract surgery procedure using corneal/limbal relaxing incisions or manual or laser astigmatic keratotomy [7–10] or, more recently, by implanting toric IOLs or multifocal toric IOLs [11–13].

Multifocal toric IOLs offer the opportunity to correct astigmatism and achieve spectacle independence at all distances in

patients with corneal astigmatism with only one procedure [14]. This study assessed changes in the activities of everyday life and satisfaction with vision in patients with implantation of a multifocal toric IOL (M-flex T, Rayner Hove, UK) in a single site series of 35 eyes of 20 patients.

## Patients and Methods

This was a prospective, non-randomized study enrolling cataract patients with preoperative corneal astigmatism of values higher than 1.5 D. The study enrolled adult patients meeting the eligibility criteria; desire for near and intermediate distance vision correction, in addition to correction of their astigmatism. The study was performed at the Department of Ophthalmology, University Center of Ophthalmology and Oncology, Silesian University of Medicine, Katowice, Poland, in accordance with the Declaration of Helsinki and Good Clinical Practice. A risk/benefit analysis was performed to identify patients suitable for multifocal toric IOL implantation.

The primary requirement for inclusion was a cataract in one or both eyes, as well as the presence of preoperative corneal regular astigmatism  $>1.5$  D. The exclusion criteria included corneal



astigmatism <1.5 D cylinder, irregular astigmatism and any diseases that could lead to it, patients who were aphakic in one eye or those who had undergone corneal refractive surgery, as well as patients with diabetes or severe microangiopathy.

### Preoperative assessments and surgical procedure

All patients were operated on by a single surgeon (EMK). Preoperatively, the cornea was marked to facilitate placement of the IOL, first with the patient at the slit lamp, and then when the patient was in the supine position. The lens implantation axis was determined using images from the Raytrace toric calculator and a protractor scale tool, using the two previously marked reference points.

All patients underwent standard phacoemulsification of the cataract under sterile conditions in the operating theatre. Topical anesthesia was used for all patients with a 2% lidocaine hydrochloride gel (Lignocainum hydrochloricum, Jelfa SA, Poland) administered before surgery and a 2% solution during the surgery.

The surgical procedure was started with a two-side paracentesis – nasal and temporal – via which a viscoelastic material, 3% sodium hyaluronate (Rayvisc, Rayner, Hove, UK), was injected into the anterior chamber, followed by creation of a 2.65–2.75 mm corneal incision. After creation of the capsulorhexis and hydrodissection/delineation, phacoemulsification was performed to remove the cataract, followed by irrigation and aspiration. The capsular bag was refilled with viscoelastic, followed by implantation of the M-flex T IOL (Rayner Inc, UK). The lens was rotated into the appropriate axis according to the preoperative corneal marks. Finally, the viscoelastic was removed and the wound sealed. At the end of surgery, the IOL axis placement was checked again and, if necessary, repositioned.

### Intraocular lens

The patients in this study received the Rayner M-flex T; model 638F/588F (Rayner, Hove, UK). This is a multifocal, aspheric, toric IOL made of hydrophilic acrylic. It is a multi-zoned, refractive IOL with either four or five annular zones (depending on IOL base power). The optic diameter is 5.75 or 6.25 mm and the overall diameter is 12.0 or 12.5 mm (dependent on spherical equivalent). Available spherical powers range from +14.0 D to +32.0 D in 0.50 D increments. The lens is also available with a near addition (add) of both +3.00 D and +4.00 D, although the present study used only the +4.00 D add. Cylinder powers range from +1.00 to +6.00 D in 0.50 D increments. The IOL power was calculated using an online toric calculator (Raytrace, Rayner, Hove, UK).

Postoperatively, patients were prescribed antibiotic eye drops (levofloxacin) 5 times per day for 7 days, corticosteroid eye drops (0.1% dexamethasone) 4 times per day for 3 weeks, a non-steroid anti-inflammatory drug (0.1% diclofenac) 3 times per day for 3 weeks, as well as dexamethasone ophthalmic gel once daily and artificial tears (depending on the needs of the patient).

### Postoperative assessment

Postoperative examinations were performed at 1 day, 1 week, 1 month, 3 months, 6 months and a final visit between 12 and 48 months after surgery. The primary outcome measures were visual acuity at different distances and spherical and cylindrical error. At the final visit, contrast sensitivity and patient satisfaction were also assessed.

### Statistical analysis method

Summary statistics are provided for key variables and have been reported as the number of non-missing values, mean, standard deviation, minimum, and maximum.

Visual acuity (VA) and subjective refraction results were compared between visits using the Friedman test. Where significant differences were found between visits, the Wilcoxon signed ranks

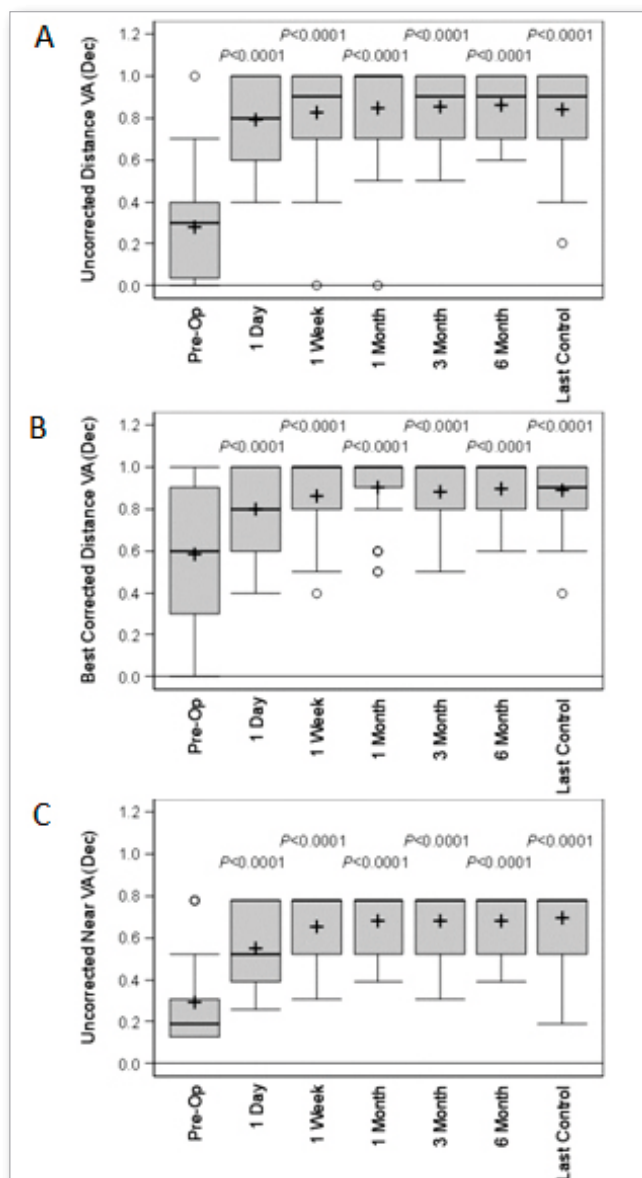
test was used to evaluate differences between the preoperative visit and the six postoperative visits. Contrast sensitivity and patient questionnaire results were only collected at the preoperative and last follow-up visits; therefore the Wilcoxon signed ranks test was used to evaluate differences between these visits. Association between VA and patient questionnaire results were analyzed using Spearman rank correlations.

All inferences were performed using SAS software Version 9.4 (SAS Institute, Cary, NC). A *p*-value of less than or equal to 0.050 was taken to indicate a statistically significant difference. For the pairwise comparisons, the Bonferroni method was used to correct for multiple tests, giving an alpha of  $0.05/6 = 0.0083$ .

## Results

### Demographics

The study enrolled 20 patients, with 35 eyes included in the analysis (15 patients had bilateral implantation). The age ranged from 25 to 69 years (mean age 57.6 years). The follow-up after IOL implantation was up to 48 months.



**Fig. 1.** Summary of uncorrected distance visual acuity (VA) (A), best corrected distance VA (B) and uncorrected near VA (C). Box and whisker plot showing the median (black line in box), mean (+), quartiles (box), and outliers (o). P-values are from the Wilcoxon test, where  $P \leq 0.0083$  is taken to indicate a significant difference.

	Preop	1 Day postop	1 week postop	1 month postop	3 months postop	6 months postop	Last control
<b>Binocular Distance VISUAL ACUITY</b>							
<b>Mean</b>	0.46	0.86	0.90	0.91	0.94	0.96	0.96
<b>SD</b>	±0.29	±0.19	±0.18	±0.15	±0.13	±0.10	±0.11
<b>Range</b>	(0.04-1.00)	(0.40-1.00)	(0.30-1.00)	(0.50-1.00)	(0.50-1.00)	(0.70-1.00)	(0.60-1.00)
<b>P-value</b>		<0.0001	<0.0001	<0.0001	<0.0001	<0.0001	<0.0001
<b>Binocular Near VISUAL ACUITY</b>							
<b>Mean</b>	0.45	0.65	0.70	0.72	0.71	0.73	0.73
<b>SD</b>	±0.25	±0.18	±0.14	±0.12	±0.14	±0.11	±0.10
<b>Range</b>	(0.13-0.78)	(0.26-0.78)	(0.39-0.78)	(0.39-0.78)	(0.31-0.78)	(0.39-0.78)	(0.52-0.78)
<b>P-value</b>		<0.0005	<0.0001	<0.0001	<0.0001	<0.0001	<0.0001

**Tab. 1.** Tab. 1. Summary of binocular distance and near visual acuity results.

### Visual acuity

The mean uncorrected distance visual acuity (UDVA) increased significantly from  $0.28 \pm 0.23$  (range 0.00–1.00) preoperatively to  $0.85 \pm 0.18$  (range 0.50–1.00) at 3 months postoperatively ( $P < 0.0001$ ) (Fig. 1). This difference was statistically significant through all follow-up visits (1 week, 1 month, 3 months, 6 months and the last follow-up) (Fig. 1A). Likewise, the corrected distance visual acuity (CDVA) improved significantly from  $0.68 \pm 0.34$  (range 0.00–1.00) to  $0.88 \pm 0.16$  (range 0.50–1.00) at 3 months ( $P < 0.0001$ ). The difference remained significant at all follow-up visits (Fig. 1B). The uncorrected near visual acuity (UNVA) increased significantly from  $0.29 \pm 0.21$  (range 0.13–0.78) to  $0.68 \pm 0.15$  (range 0.31–0.78) at 3 months ( $P < 0.0001$ ) (Fig. 1C).

The binocular distance and near visual acuity also improved, as summarized in Table I. Binocular distance vision was stable by one month postoperatively, while binocular near vision stabilized by three months.

### Refraction

The mean spherical refraction improved from  $+1.10$  D,  $\pm 2.65$  D (range -6.00 to +6.75 D) preoperatively to  $-0.05 \pm 0.26$  (range -1.25 to +0.25 D) ( $P = 0.014$ ) at the 3-month postoperative visit (Fig. 2A).

The mean preoperative cylinder was  $-2.15 \pm 1.58$  D, range -6.50 to 1.5 D (Fig. 2B), which improved to  $-0.01 \pm 0.43$  D (range -1.00 to +2.00) at the 3-month postoperative follow-up.

### Contrast sensitivity

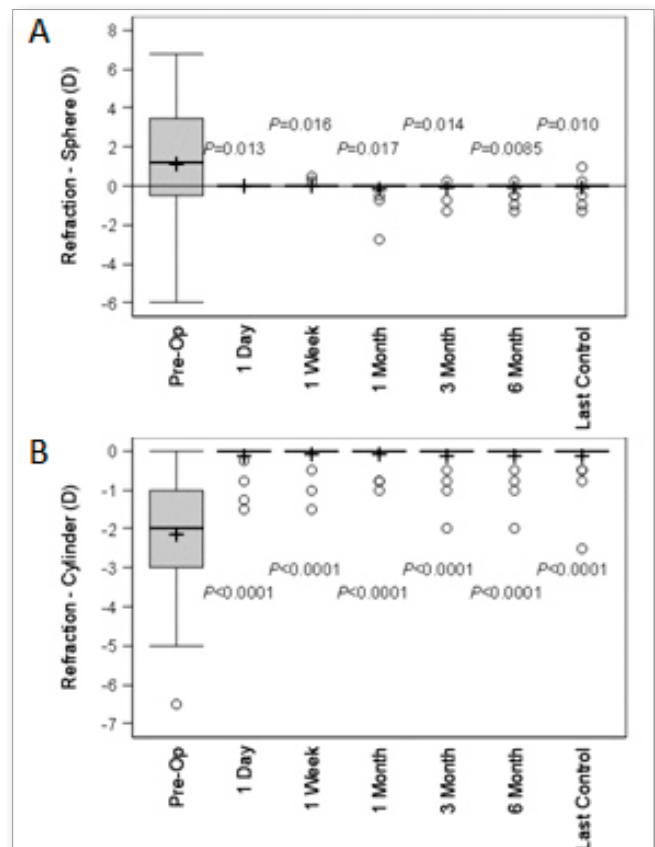
All patients demonstrated an improvement in contrast sensitivity following cataract removal and implantation of the M-flex T IOL. This was evident throughout all spatial frequencies of 3, 6, 12 and 18, through to the last postoperative visit (Fig. 3).

### Patient satisfaction

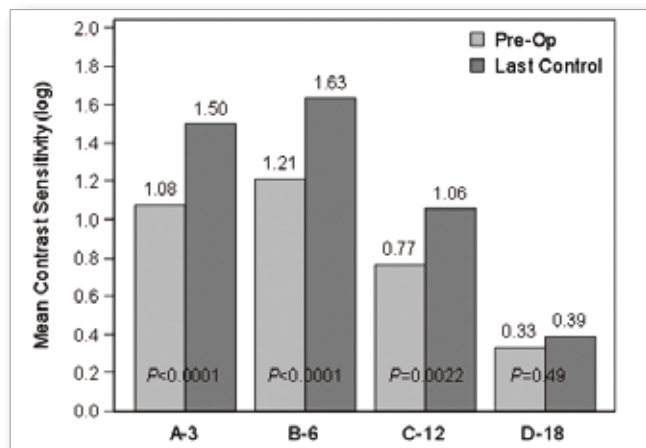
Patient satisfaction after multifocal toric IOL implantation was measured with the VF-14 questionnaire [15]. Overall, patient satisfaction was significantly higher after surgery, 82.67% compared to 41.62% before surgery ( $p = 0.0017$ ) (Fig. 4A). The difference between the preoperative and the postoperative follow-up scores for "spectacle dependence" was even more significant, 14.58 vs. 90.20 ( $P < 0.001$ ) (Fig. 4A). Furthermore, a scatter plot revealed a positive correlation between patient satisfaction and UCVA (correlation  $p = 0.33$ ) (Fig. 4B). There were no intraoperative complications, and postoperative complications were rare.

### Discussion

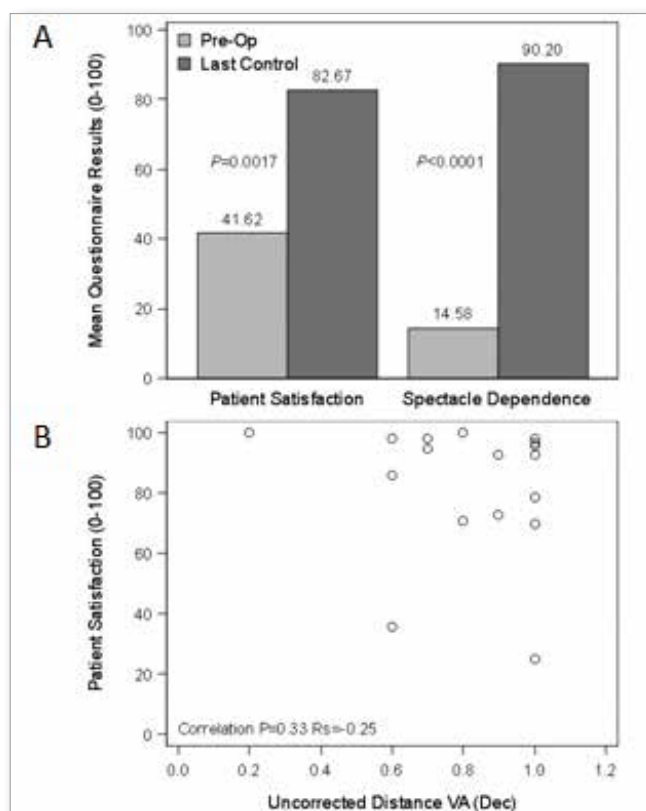
In the past decade, there have been major advancements in the development of safe and predictable toric IOLs. Several studies with clinical, optical, functional and quality of life measures have shown that new-generation intraocular lenses improve near vision whilst continuing to provide good distance vision [8, 16–19]. In a large randomized clinical study, Holland et al. [20] compared the AcrySof Toric IOL and a control IOL to investigate visual acuity outcomes of the AcrySof Toric IOL in subjects with cataract and preexisting corneal astigmatism. Two hundred and fifty-six



**Fig. 2.** Summary of subjective refraction sphere power (A) and subjective refraction cylinder power (B). Box and whisker plot showing the median (black line in box), mean (+), quartiles (box), and outliers (o). P-values are from the Wilcoxon test, where  $P \leq 0.0083$  is taken to indicate a significant difference.



**Fig. 3.** Boxplot showing contrast sensitivity at 3, 6, 12, and 18 cycles/degree. P-values are from the Wilcoxon test, where  $P \leq 0.050$  is taken to indicate a significant difference.



**Fig. 4.** (A) Boxplot showing patient questionnaire results. P-values are from the Wilcoxon test, where  $P \leq 0.050$  is taken to indicate a significant difference. (B) Scatter plot showing patient satisfaction and uncorrected distance visual acuity (VA). Spearman's rank correlation coefficient is included.

participants received the toric IOL and 261 received the control IOL. After one year 77% of the toric IOL group had best spectacle-corrected distance visual acuity of  $\geq 20/20$  compared with 69.2% of the control IOL group. The UDVA of 20/20 or better was 40.7% in the toric IOL group compared to 19.4% in the control IOL group ( $p < 0.05$ ). Mean absolute residual refractive cylinder was 0.59 D (toric IOL) vs. 1.22 D ( $P < 0.001$ ). Furthermore, six-month spectacle freedom was 61% in the toric IOL group compared to 36.4% in the control IOL group ( $p < 0.001$ ). It was concluded that the AcrySof Toric IOL had favorable efficacy and distance vision over the control IOL.

In the current study, we evaluated visual and refractive outcomes, contrast sensitivity and patient satisfaction after implan-

tation of the Rayner M-flex T. The non-toric Rayner multifocal IOLs, which share the same platform as the Rayner M-flex T, have been evaluated in other studies. In a study on the M-flex 630F (+3.00 D add) IOL, a mean monocular CDVA of 0.03 logMAR (approximately 20/20) was reported 12 months after surgery [21]. The binocular uncorrected and corrected near acuities were 0.25 logMAR and 0.03 logMAR respectively after 6 months [21]. No dysphotopic phenomena were reported. To our knowledge, the only publication to date to evaluate Rayner's M-flex T IOL is by Shimoda et al. [22]. In this study, three months after the surgery, the mean CDVA was 0.00 logMAR at 6 m, 0.20 logMAR at 70 cm and 0.08 logMAR at 40 cm. The preoperative mean refractive cylinder of -2.19 D decreased to -0.44 D, with 87.5% of patients spectacle free.

Overall, our data confirm Shimoda and coworkers' findings. The CDVA improved significantly from  $0.58 \pm 0.34$  (range 0.00–1.00) to  $0.80 \pm 0.21$  (range 0.40–1.00) after 1 day and remained strongly significant throughout all the follow-up visits ( $p < 0.001$ ). There are a number of studies describing refractive outcome after multifocal toric IOL implantation [8, 23, 24]. Specifically, a binocular logMAR CDVA of -0.06 and 0.05 after 3 months of follow-up has been reported using the AT Lisa (Carl Zeiss Meditec, Jena Germany) multifocal toric IOL [8, 16].

The UDVA in our study increased significantly from 0.28 before surgery to 0.79 after 1 day ( $p < 0.001$ ) and it remained at the same level during the follow-up visits. Using the Rayner M-flex 630F IOL, Cezón Prieto and Bautista found a mean UDVA of 0.09 logMAR (approximately 20/25) 12 months after surgery, with 100% of eyes achieving a UDVA of 0.30 logMAR (20/40) or better and 75% of eyes achieving a UDVA of 0.00 logMAR (20/20) or better [14]. The work by Visser et al. showed similar results using the AT Lisa multifocal toric IOL, with a mean monocular logMAR UDVA of 0.04 after surgery; 98% of eyes had a UDVA of 0.30 logMAR (20/40) or better and 71% of eyes had a UDVA of 0.10 logMAR (20/25) or better [8].

In our study, the Rayner M-flex T IOL with +4.00 D add provided good performance for near vision, as the UNVA improved significantly from  $0.29 \pm 0.21$  (range 0.13 to 0.78) to 0.68, 0.15 (range 0.31 to 0.78) at 3 months ( $p < 0.001$ ), with no change through to the final postoperative visit. This is comparable to published data on other multifocal IOLs [11, 17, 18, 25]. In the study by Visser et al. [11], the mean UNVA was 0.20 logMAR. In another study of a multifocal toric IOL by Alió et al. [23], the mean postoperative UNVA and CDVA were 0.24 and 0.24 logMAR, respectively, at 3 months. Cezón Prieto and Bautista reported a UNVA value of 0.28 logMAR in eyes implanted with the Rayner M-flex IOL [14]. Moreover, in our study the implantation of the M-flex T IOL significantly improved the binocular distance and near VA. It was also observed that the rehabilitation was completed within 1 month for binocular distance VA and within three months for binocular near VA.

The mean residual cylinder power achieved in this study was  $-0.11 \pm 0.34$  D one day after surgery, compared to  $-2.15 \pm 1.58$  D preoperatively ( $p < 0.001$ ). This is in line with Shimoda's [15] and Holland's [13] findings described above.

As with all multifocal IOLs, there can be a reduction in contrast sensitivity due to the distribution of total available light between several focal points. Previous works [12, 26, 27] have reported lower photopic contrast sensitivity with a multifocal IOL than with a monofocal IOL, while the contrast sensitivity was still in the normal range. Pomerance et al. [28] observed that, in a normal population, contrast sensitivity levels measured with the CSV-1000 system were  $1.56 \pm 0.15$  at 3 cycles per degree (cpd),  $1.80 \pm 0.16$  at 6 cpd,  $1.50 \pm 0.15$  at 12 cpd, and  $0.93 \pm 0.25$  at 18 cpd. This indicated that in our study the contrast sensitivity

after Rayner M-flex T implantation was comparable with that in the normal population at 2 spatial frequencies (3 and 6 cpd) and decreased at high spatial frequencies (12 and 18 cpd).

Overall, the patient satisfaction in this study after multifocal toric IOL implantation was high. Using the VF-14 instrument, the overall satisfaction after surgery was 82.67%, compared with 41.62% before surgery, and spectacle dependence was 90.2% after surgery, compared with 14.6% before surgery. This is comparable to the results of Mingo-Botin et al. [29], who found that patient satisfaction increased from 60.13 to 90.73 and spectacle dependence decreased for patients treated with toric IOLs from 40% to 0% of those who always used spectacles.

This study shows that implantation of a multifocal toric IOL is a good option for cataract patients motivated to reduce their dependency on glasses. The visual function index was high immediately after surgery and remained at the same level up to the last follow-up. The high level of patient satisfaction confirms the efficacy of the surgery.

#### Disclosure

Conflict of interests: none declared

Funding: no external funding

Ethics approval: Not applicable.

#### Financial Disclosure:

No financial or proprietary interest in any material or method has been reported.

The authors have no proprietary or commercial interest in the medical devices that are mentioned in this manuscript.

#### References:

- Javitt JC, Wang F, West SK: *Blindness due to cataract: epidemiology and prevention*. Annu Rev Public Health. 1996; 17: 159–177.
- Thulasidas M, Kadam A: *Toric intraocular lens: A literature review*. Taiwan J Ophthalmol. 2021 Dec 10; 14(2): 197–208. doi: 10.4103/tjo.tjo\_43\_21.
- Hoffmann PC, Hutz WW: *Analysis of biometry and prevalence data for corneal astigmatism in 23,239 eyes*. J Cataract Refract Surg. 2010; 36(9): 1479–1485.
- Ferrer-Blasco T, Montes-Mico R, Peixoto-de-Matos SC, et al.: *Prevalence of corneal astigmatism before cataract surgery*. J Cataract Refract Surg. 2009; 35(1): 70–75.
- Vitale S, Ellwein L, Cotch MF, et al.: *Prevalence of refractive error in the United States, 1999–2004*. Arch Ophthalmol. 2008; 126: 1111–1119.
- Frohn A, Dick HB, Thiel HJ: *Implantation of a toric poly(methylmethacrylate) intraocular lens to correct high astigmatism*. J Cataract Refract Surg. 1999; 25(12): 1675–1678.
- Inoue T, Maeda N, Sasaki K, et al.: *Factors that influence the surgical effects of astigmatic keratotomy after cataract surgery*. Ophthalmology. 2001; 108: 1269–1274.
- Muller-Jenson K, Fischer P, Siepe U: *Limbal relaxing incisions to correct astigmatism in clear corneal cataract surgery*. J Refract Surg. 1999; 15: 586–589.
- Artola A, Ayala MJ, Claramonte P, et al.: *Photorefractive keratectomy for residual myopia after cataract surgery*. J Cataract Refract Surg. 1999; 25: 1456–1460.
- Pop M, Payette Y, Amyot M: *Clear lens extraction with intraocular lens followed by photorefractive keratectomy or laser in situ keratomileusis*. Ophthalmology. 2001; 108: 104–111.
- Visser N, Nuijts RM, de Vries NE, et al.: *Visual outcomes and patient satisfaction after cataract surgery with toric multifocal intraocular lens implantation*. J Cataract Refract Surg. 2011; 37(11): 2034–2042.
- Gabrić K, Gabrić N, Piñero DP, et al.: *Comparative Analysis of the Clinical Outcomes of Two Toric Presbyopia-Correcting Intraocular Lenses*. Ophthalmol Ther. 2024 Mar; 13(3): 775–790. doi: 10.1007/s40123-023-00878-8.
- Kabbani J, Price L, Patel R, et al.: *A survey of intraocular lens preferences of UK refractive surgeons for cataract surgery and refractive lens exchange*. BMC Ophthalmol. 2024 Sep 6; 24(1): 397. doi: 10.1186/s12886-024-03639-8.
- Shi R, Ma D, Zeng Q, et al.: *Rotational stability of monofocal and diffractive multifocal toric intraocular lens with identical design and material: a propensity score based prospective comparative study*. BMC Ophthalmol. 2024 Feb 16; 24(1): 72. doi: 10.1186/s12886-024-03281-4.
- Steinberg EP, Tielsch JM, Schein OD, et al.: *The VF-14. An index of functional impairment in patients with cataract*. Arch Ophthalmol. 1994; 112: 630–638.
- Chang DF: *Prospective functional and clinical comparison of bilateral ReZoom and ReSTOR intraocular lenses in patients 70 years or younger*. J Cataract Refract Surg. 2008; 34(6): 934–941.
- Pepose JS, Qazi MA, Davies J, et al.: *Visual performance of patients with bilateral vs combination Crystalens, ReZoom, and ReSTOR intraocular lens implants*. Am J Ophthalmol. 2007; 144(3): 347–357. Comment in: Am J Ophthalmol. 2008; 145(4): 593–594.
- Alió JL, Plaza-Puche AB, Piñero DP, et al.: *Quality of life evaluation after implantation of 2 multifocal intraocular lens models and a monofocal model*. J Cataract Refract Surg. 2011; 37(4): 638–648.
- Köppe MK, Auffarth GU, Son HS, et al.: *Evaluation of Long-term Rotational Stability and Functional Performance of Two Toric Multifocal IOL Models Beyond 5 Years*. J Refract Surg. 2024 Nov; 40(11): e845–e853. doi: 10.3928/1081597X-20241002-05.
- Holland E, Lane S, Horn JD, et al.: *The AcrySof Toric intraocular lens in subjects with cataracts and corneal astigmatism: a randomized, subject-masked, parallel-group, 1-year study*. Ophthalmology. 2010; 117(11): 2104–2111.
- Cezón Prieto J, Bautista MJ: *Visual outcomes after implantation of a refractive multifocal intraocular lens +3.00 D addition*. J Cataract Refract Surg. 2010; 36(9): 1508–1516.
- Shimoda T, Shimoda G, Hida WT, et al.: *Visual outcomes after implantation of a novel refractive toric multifocal intraocular lens*. Arq Bras Oftalmol. 2014 Apr; 77(2): 71–75.
- Alió JL, Piñero DP, Tomás J, et al.: *Vector analysis of astigmatism changes after cataract surgery with implantation of a new toric multifocal intraocular lens*. J Cataract Refract Surg. 2011; 37(7): 1217–1229.
- Liekfeld A, Torun N, Friederici L: *A new toric diffractive multifocal lens for refractive surgery*. Ophthalmologie. 2010; 107(3): 256, 258–261.
- Alfonso JF, Fernández-Vega L, Amhaz H, et al.: *Visual function after implantation of an aspheric bifocal intraocular lens*. J Cataract Refract Surg. 2009; 35(5): 885–892.
- Muñoz G, Albarrán-Diego C, Ferrer-Blasco T, et al.: *Visual function after bilateral implantation of a new zonal refractive aspheric multifocal intraocular lens*. J Cataract Refract Surg. 2011; 37(11): 2043–2052.
- Montés-Micó R, España E, Bueno I, et al.: *Visual performance with multifocal intraocular lenses; mesopic contrast sensitivity under distance and near conditions*. Ophthalmology. 2004; 111: 85–96.
- Pomerance GN, Evans DW: *Test-retest reliability of the CSV-1000 contrast test and its relationship to glaucoma therapy*. Invest Ophthalmol Vis Sci. 1994; 35(9): 3357–3361.
- Mingo-Botin D, Muñoz-Negrete FJ, Won Kim HR, et al.: *Comparison of toric intraocular lenses and peripheral corneal relaxing incisions to treat astigmatism during cataract surgery*. J Cataract Refract Surg. 2010 Oct; 36(10): 1700–1708.

#### Reprint requests to:

Professor Ewa Mrukwa-Kominek, MD, PhD (e-mail: ewa.mrukwa@sum.edu.pl)  
Department of Ophthalmology, Professor K. Gibinski University Clinical Center,  
Medical University of Silesia, Katowice, Poland  
ul. Ceglana 35, 40-514 Katowice