

Optic Chiasmitis as an Isolated Manifestation of Myelin Oligodendrocyte Glycoprotein-Associated Disease – a Case Report

Nina Barankiewicz-Tyc, Karolina Kania, Wojciech Kozubski

Department of Neurology, Poznan University of Medical Sciences, Poznań, Poland
Head: prof. dr hab. n. med. Wojciech Kozubski

Abstract:

Introduction: The most common cause of chiasmopathy is compression of the optic chiasm by parasellar tumours. The tumours may produce any pattern of visual field defect depending on the tumour location and the patient's chiasm anatomy. Rare, non-compressive causes of chiasmopathy include, among others, infectious, post-infectious, inflammatory, autoimmune, demyelinating, toxic and ischaemic processes. Chiasmopathy can also occur due to trauma and radiation treatment.

Case report: We report a case of a 43-year-old patient who was admitted to our department because of a two-month history of headaches and constant, symmetrical blurriness over the temporal sides of vision. After a wide-ranging diagnostic process, the patient was diagnosed with an isolated optic chiasmitis in the course of myelin oligodendrocyte glycoprotein-associated disease, which is a rare, monophasic or relapsing, antibody-mediated inflammatory demyelinating disorder of the central nervous system.

Conclusions: It is crucial to remember that parasellar tumours are not the only cause of bitemporal hemianopsia. Patients with bitemporal hemianopsia, if there is no compressive lesion of the optic chiasm, should be investigated for optic chiasmitis. Optic chiasmitis is not a diagnosis in itself, but a sign of an underlying pathology, and during its evaluation should be treated as a variation of atypical optic neuritis. We hope that this ophthalmic manifestation of a rare neurological disease will make other clinicians aware of the utter importance of careful evaluation of visual disturbances.

Key words:

bitemporal hemianopsia, optic chiasmitis, optic chiasm, chiasmopathy, myelin oligodendrocyte glycoprotein-associated disease (MOGAD), parasellar tumours.

Introduction

1. A patient presenting with bitemporal hemianopsia was diagnosed with myelin oligodendrocyte glycoprotein-associated disease (MOGAD).
2. It is crucial to remember that parasellar tumours are not the only cause of bitemporal hemianopsia.
3. Patients with bitemporal hemianopsia, if there is no compressive lesion of the optic chiasm, should be investigated for optic chiasmitis.
4. Optic chiasmitis is not a diagnosis in itself, but a sign of an underlying pathology.
5. Optic chiasmitis during its evaluation should be treated as a variation of atypical optic neuritis.

Case report

A 43-year-old Caucasian man presented with a two-month history of headaches and constant, symmetrical blurred vision in the temporal halves of the visual field of each eye (with no spontaneous improvement).

Apart from this, he denied diplopia, eye pain, bladder dysfunction and any other neurological signs or symptoms. His past medical history was remarkable only for migraine. He was on no medication. His family history was non-contributory. He did not smoke cigarettes or consume alcohol. There was no precipitating factor: he denied recent infection, vaccination, trauma, travel, contacts with pets or any history of sexually transmitted disease. COVID-19 had occurred a year earlier.

Neurological and ophthalmic examinations were normal. Ocular motility was full. There was no ptosis, anisocoria or nystagmus. His visual acuity was 20/20 in each eye (OU). Both pupils were reactive to light. There was no relative afferent pupillary defect or near-light dissociation. Fundus examination showed

normal discs, with a cup-to-disc ratio of 0.2 OU. OCT was normal OU (Fig. 1, 2).

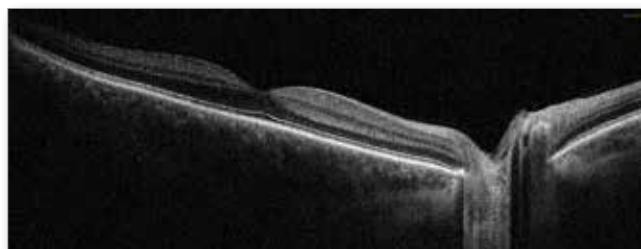

Fig. 1. OCT image of a healthy fovea and optic disc (right eye).

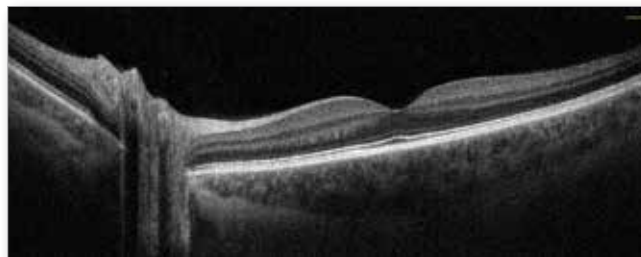


Fig. 2. OCT image of a healthy fovea and optic disc (left eye).

However, the patient complained of constant blurriness over the temporal sides of vision. A confrontation visual field test revealed bitemporal hemianopsia (or, more precisely, bitemporal hemidysopsia). Automated visual field testing (Humphrey) was normal OU, yet not reliably – the aim of the test was to mark the borders of blurred areas; however, every time the patient saw a bright stimulus, he pressed a button on a handheld remote con-

tol, regardless of whether the stimulus was localized in the affected area or not (he was able to see the stimulus breaking through “greyish clouds”).

Our later workup included MR angiography and venography of the brain and pituitary magnetic resonance imaging MRI (with gadolinium contrast) and orbital MRI (unfortunately without gadolinium contrast), which were normal. Cerebral venous sinus thrombosis was excluded. No white matter lesions were detected on T2 FLAIR sequences. No cause of compressive chiasmopathy was found.

Lumbar puncture showed an elevated protein level in cerebrospinal fluid (652 mg/ l). The IgG index was normal (0.48). Oligoclonal bands were absent. Cerebrospinal fluid was negative for syphilis and Lyme disease.

We also conducted serum testing for full blood count, liver function, glucose, electrolytes, CRP, ESR; ANA, ANCA, RF, angiotensin converting enzyme (ACE); QuantiFERON-TB Gold Plus; HSV-I, HSV-II, VZV, HIV, CMV; hepatitis B and C; bartonellosis, brucellosis, toxoplasmosis, toxocarriasis, schistosomiasis; syphilis, Lyme disease, mononucleosis; MOG-IgG and AQP4-IgG antibodies; vitamin B12; pituitary hormones; and stool testing for cryptosporidiosis.

Once all samples had been collected, one gram of intravenous methylprednisolone was administered daily for six days, followed by an oral prednisone taper at home. The patient was highly responsive to intravenous steroids – visual disturbances did not vanish completely, but, already after the first dose, the areas of blurriness bilaterally shrank substantially.

On the basis of normal chest high resolution computed tomography (HRCT) and unelevated serum ACE level a suspicion of neurosarcoidosis was ruled out. The pituitary hormone levels were within normal ranges, and the patient did not present signs and symptoms related to hypophysitis (inflammation of the pituitary gland that, as we thought, might have transferred to the optic chiasm).

In the meantime, we received the serum results. They were all negative, except for MOG-IgG antibodies (Fig. 3), which were positive at a titre of 1: 10. Serum AQP4-IgG antibodies were not detected.

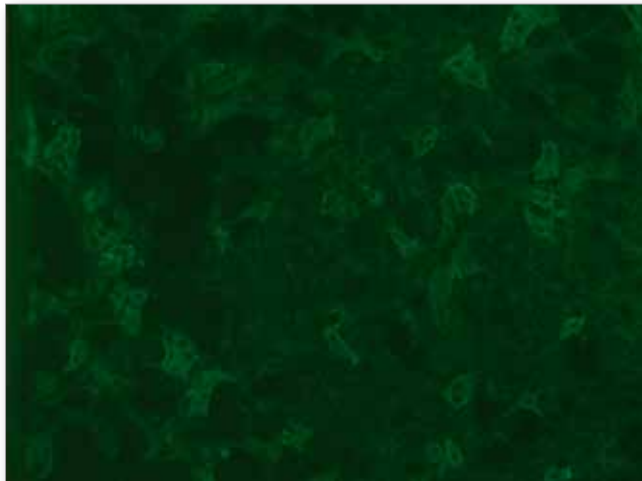


Fig. 3. Serum positive for MOG-IgG antibodies (titre 1: 10). Testing was performed using fCBA-IF (Euroimmun). (Photo courtesy of the Department of Neurochemistry and Neuropathology, Poznan University of Medical Sciences).

Although the patient did not meet the International MOGAD Panel proposed criteria published by Brenda Banwell, et al. in *The Lancet Neurology* on January 24, 2023 [1] (a low positive assay result with no supporting clinical or MRI feature), given the presence of bitemporal hemianopsia (which is a localizing sign for

the optic chiasm [2]), no optic chiasm lesion, elevated cerebrospinal fluid protein level, serum MOG-IgG antibody positivity, excellent response to intravenous steroid treatment and exclusion of better diagnoses (including multiple sclerosis), the diagnosis of optic chiasmitis in the course of MOGAD was made. We strongly believe that enhancement of the optic chiasm would be observed in orbital MRI if a radiologist agreed to administer contrast.

The patient was discharged with incomplete, but significant, visual recovery.

Conclusions

Optic chiasmitis can produce a bitemporal visual field defect that can mimic the presentation of optic chiasm lesions caused by parasellar tumours [3] – e.g.: pituitary neuroendocrine tumours [PitNETs], craniopharyngiomas, meningiomas, Rathke cleft cysts [4] – and suprasellar aneurysms – internal carotid artery aneurysm, anterior communicating artery aneurysm [2]. The tumours may produce any pattern of visual field defect – including bitemporal hemianopsia and, if a lesion is at the junction of the optic nerve and the optic chiasm, junctional scotoma of Traquair [5] – depending on the tumour location and the patient’s chiasm anatomy [3].

Bitemporal hemianopsia is a localizing sign and suggests a problem at the level of the optic chiasm [2]; thus, after excluding compressive, traumatic, ischaemic and iatrogenic – radiation-induced, past-surgical, associated with some medications [6] – chiasmopathies and arachnoiditis [6], we encourage consideration of optic chiasmitis and performance of further evaluation for conditions such as atypical optic neuritis. Ischaemic strokes of the optic chiasm are very rare due to its rich vascularisation by multiple arteries of the circle of Willis [6].

However, let us not forget about pseudobitemporal hemianopsia. Ophthalmic causes of pseudobitemporal hemianopsia include tilted disc syndrome (TDS), optic nerve hypoplasia (ONH) and acute zonal occult outer retinopathy (AZOOR), along with a syndrome thought to represent a spectrum of disease: acute idiopathic blind-spot enlargement (AIBSE) [7]. Neurological causes of pseudobitemporal hemianopsia comprise, theoretically, bilateral temporal crescent syndrome – also known as half-moon syndrome [8] produced by bilateral, symmetrical retrochiasm lesions in anteromedial occipital cortexes and simultaneous damage to the nasal retinal fibres from both optic nerves (before the optic chiasm).

And, last but not least, MOGAD, a rare, monophasic or relapsing, antibody-mediated inflammatory demyelinating disorder of the central nervous system [9] is typically associated with acute disseminated encephalomyelitis, transverse myelitis or optic neuritis.

Optic neuritis in MOGAD presents atypically: it is frequently bilateral and anterior at onset, longitudinally extensive and involving the optic nerve sheath, with moderate to severe oedema [1].

Some cases of patients with MOGAD (and neuromyelitis optica spectrum disorders [NMOSD]) with optic chiasm and other parts of visual system involvement can be found in the literature, but, to the best of our knowledge, this is the first case of isolated optic chiasmitis in the course of MOGAD that has ever been reported [10].

It is our sincere hope that this case will raise both awareness and interest in neuro-ophthalmology.

Disclosure

The authors report no conflict of interest.

Funding: The authors received no financial support for the publication of this case report.

Ethics approval: Not applicable.

Informed consent: Written consent was obtained from the patient.

References:

1. Banwell B, Bennett JL, Marignier R, et al.: *Diagnosis of myelin oligodendrocyte glycoprotein antibody-associated disease: International MOGAD Panel proposed criteria*. The Lancet Neurology. 2023; 22(3): 268–282. DOI: [https://doi.org/10.1016/S1474-4422\(22\)00431-8](https://doi.org/10.1016/S1474-4422(22)00431-8).
2. Pane A, Miller NR, Burdon M: *The neuro-ophthalmology survival guide*. 2nd edition. Elsevier, 2018: p. 13, 29–30, 32, 65, 86–92, 100, 360–361.
3. Lee AG, Al Zubidi N, Spitze A: *Questions and answers in neuro-ophthalmology: a case-based approach*. World Scientific Publishing. 2014: p. 197–209.
4. Ugga L, Franca RA, Scaravilli A, et al.: *Neoplasms and tumor-like lesions of the sellar region: imaging findings with correlation to pathology and 2021 WHO classification*. Neuroradiology. 2023; 65(4): 675–699. DOI: [10.1007/s00234-023-03120-1](https://doi.org/10.1007/s00234-023-03120-1).
5. Donaldson LC, Eshtiaghi A, Sacco S, et al.: *Junctional Scotoma and Patterns of Visual Field Defects Produced by Lesions Involving the Optic Chiasm*. Journal of Neuro-Ophthalmology. 2022; 42(1): 203–208. DOI: [10.1097/WNO.0000000000001394](https://doi.org/10.1097/WNO.0000000000001394).
6. Sigireddi RR, Bhat N, Raviskanthan S, et al.: *Bitemporal hemianopsia secondary to ischemic chiasmopathy following mechanical thrombectomy*. American Journal of Ophthalmology Case Reports. 2021; 23. DOI: <https://doi.org/10.1016/j.ajoc.2021.101191/>
7. Wang M, Sadaka A, Prager T, et al.: *From A ... to ... Z (OOR): The Clinical Spectrum of Acute Zonal Occult Outer Retinopathy*. Neuroophthalmology. 2017; 42(4): 215–221. DOI: [10.1080/01658107.2017.1400076](https://doi.org/10.1080/01658107.2017.1400076).
8. Ali K: *The temporal crescent syndrome*. Practical Neurology. 2015; 15(1): 53–55. DOI: [10.1136/practneurol-2014-001014](https://doi.org/10.1136/practneurol-2014-001014).
9. Ambrosius W, Kozubski W, Michalak S, et al.: *Myelin Oligodendrocyte Glycoprotein Antibody-Associated Disease: Current Insights into the Disease Pathophysiology. Diagnosis and Management*. International Journal of Molecular Sciences. 2020; 22(1): 100. DOI: [10.3390/ijms22010100](https://doi.org/10.3390/ijms22010100).
10. Tajfirouz D, Padungkiatsagul T, Beres S, et al.: *Optic Chiasm Involvement in AQP-4 Antibody Positive NMO and MOG Antibody Associated Disorder*. Multiple Sclerosis Journal. 2022; 28(1): 149–153. DOI: [10.1177/13524585211011450](https://doi.org/10.1177/13524585211011450).

Reprint requests to:

Nina Barankiewicz-Tyc, MD (e-mail: ninabarankiewiczyt@gmail.com)
 Department of Neurology, Poznan University of Medical Sciences, Poznań
 49 Przybyszewskiego St., 60-355 Poznań